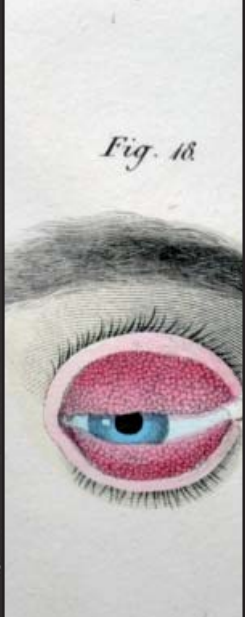
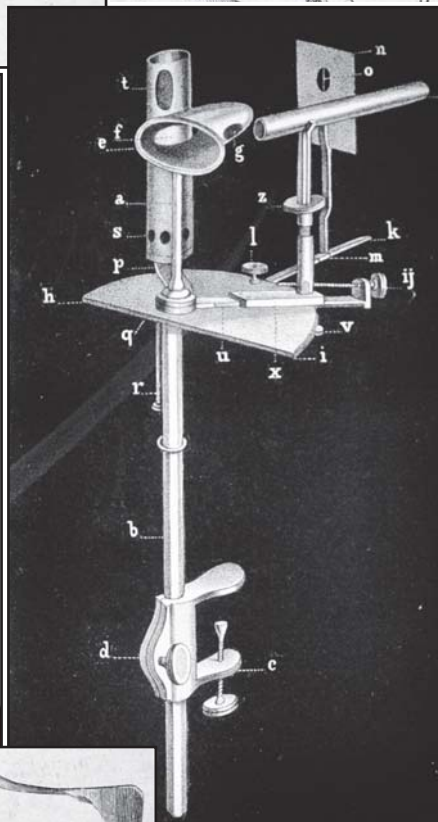
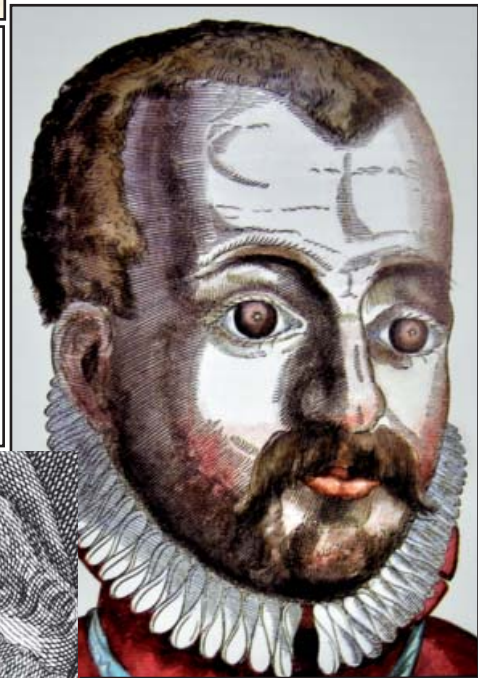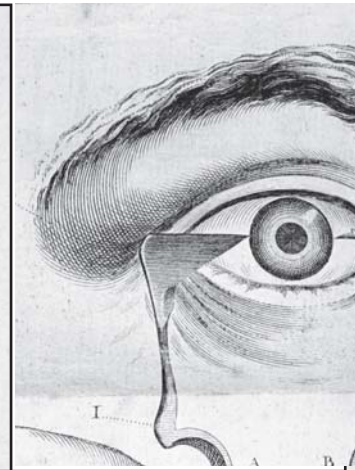



HISTORIA OPHTHALMOLOGICA INTERNATIONALIS

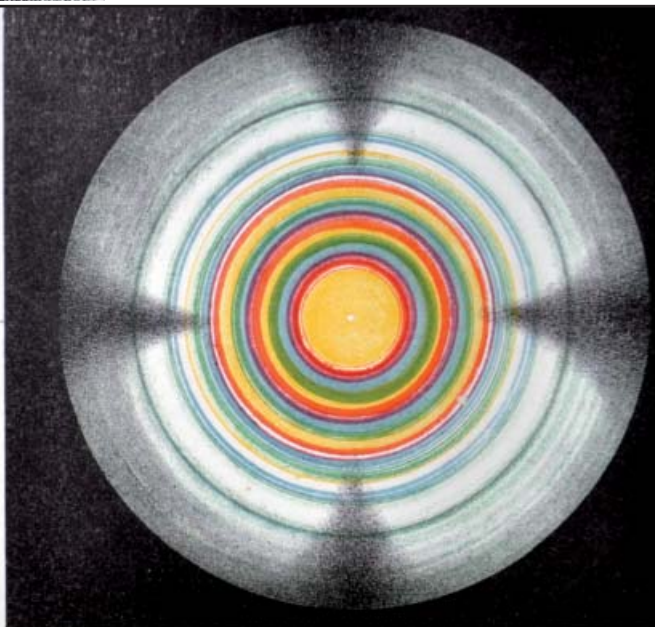
JOURNAL FOR THE HISTORY OF OPHTHALMOLOGY AND OF VISION SCIENCES

DIETER SCHMIDT & ANDRZEJ GRZYBOWSKI

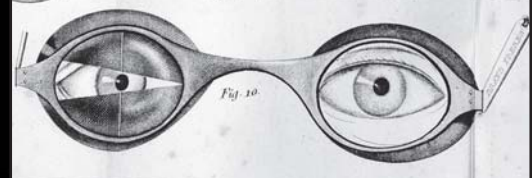
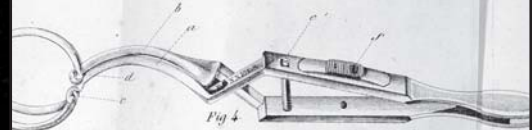

WIKTOR FELIKS SZOKALSKI, FATHER OF OPHTHALMOLOGY IN POLAND



Anneaux colorés
du Cristal de Roche, taillé
perpendiculairement à l'axe.




P. Luckerbauer chrome lith.



Imp. Desquey

Wiktor Feliks Szokalski, The Father of Ophthalmology in Poland

Dieter Schmidt ⁽¹⁾, Andrzej Grzybowski ^(2,3)



Wiktor Feliks Szokalski
1811-1891

Authors:

- 1:** Dieter Schmidt MD
Professor of Ophthalmology
Klinik für Augenheilkunde der Universität
D-79106 Freiburg, Germany
- 2.** Andrzej Grzybowski
Dept. of Ophthalmology
ul. Szwajcarska 3,
61-285 Poznan, Poland
- 3.** Chair of Ophthalmology,
University of Warmia and Mazury,
Olsztyn, Poland

Curriculum Vitae of Wiktor Feliks Szokalski¹


Born: December 15th, 1811 in Warsaw.
1827: begin of his medical studies in Warsaw.
1831: joined the Polish army; Polish decoration „Virtuti militari“; after Poland's lost war against Russia, expelled from Poland; continuation of his medical studies in Gießen.
1834: termination of his medical studies and completion of his thesis on the topic: „*De facie hippocratica*“; two-years' employment in Heidelberg and Würzburg specializing in ophthalmology.
1838: move to Paris; employed in Sichel's Eye Clinic; Szokalski gave lectures in ophthalmology up until 1848.
1839: completion of his French thesis on the topic: „*Sur la diplopie unioculaire ou la double vision d'un œil*“. Editor of the Journal »*L'Esculape*«, together with Salvatore Furnari.
1844: founder* and first president of the Society of German Physicians in Paris.
1848-1853: nomination as head of the hospital in Alice-Sainte-Reine (Burgundy); nomination as railroad physician (in Lyon).
1853: return to the Kingdom of Poland (permission by the Russian government); offered a position as professor of Ophthalmology in Warsaw; rejected by the Austrian government. Nomination as assistant medical director („Oberarzt“) at Prince Lubomirski's Institute of Ophthalmology.
1857: honorary post as lifelong secretary with editorship of the Warsaw Medical Society.
1858: nomination as director of Lubomirski's Institute of Ophthalmology. Member of the teaching staff at the Medical-Surgical Academy in Warsaw (Teacher in physiology for one year).
1861-1871: nomination as professor of ophthalmology and otology at the main hospital in Warsaw, later part of Warsaw University. Refusal to fulfill the government's obligation to give lectures in the Russian language, followed by his losing his professorship.

¹ Fischer I. „Biographisches Lexikon der hervorragenden Ärzte der letzten fünfzig Jahre“, Bd. 1-3 (1932, 1933, 2002)

Hirsch A, Gurlt E, Wernich A, (Hrsg.), 2. Auflage (Habering W, Vierordt H, Hübotter F.) Biographisches Lexikon der hervorragenden Ärzte aller Zeiten und Völker (1930, 1932, 1934)

Talko J. Jubilee of Prof. Dr. Szokalski, Klin. Monatsbl. Augenheilkd. 1879: 17: 204.

Szokalski was a member in 33 international academies, most importantly in the Cracow Scientific Academy and Ophthalmological Society Heidelberg; he died on January 1st, 1891.



Dedication page in Szokalski's German Monograph *Über die Empfindungen der Farben* (1842)

My former teachers

Georg Friedrich **Balsler** (1780-1846): Ophthalmology
 Maximilian Joseph **Chelius** (1794-1876): Surgery & Ophthalmology
 Karl **Vogt*** (born 1817-?): Physiology
 Jules **Sichel** (1802-1868): Ophthalmology

out of
Gratitude, Reverence and Love

Wayenborgh Collection

Wiktor Feliks Szokalski had an eventful life as a physician. He joined the Polish army in 1831. Szokalski was expatriated and immigrated to Germany, where he continued his medical studies in Gießen. He specialized in ophthalmology in Heidelberg and Würzburg. Later, he moved to Paris and became an assistant physician in Dr. Sichel's Ophthalmological Clinic in 1838. Szokalski gave lectures in ophthalmology in Paris. After completing his French thesis on the topic „*Sur la diplopie unioculaire ou la double vision d'un œil*“ in 1839, he became co-editor of the Journal »*L'Esculape*«. In 1844 he was the founder* and first president of the Society of German Physicians in Paris. He was

*Co-founder of this Society was his teacher Karl Vogt who also spent the years 1844-46 in Paris

nominated head of the hospital in Alice-Sainte-Reine (Burgundy) and kept that position for five years; in addition, he was nominated as railroad physician in Lyon. In 1853 he returned to the Kingdom of Poland and became director of Lubomirski's Institute of Ophthalmology in 1858. From 1861 to 1871, he was professor of ophthalmology and otology at Warsaw's main hospital, which later became part of Warsaw University. When he refused to give lectures in the Russian language, he had to leave the university. He was member of 33 international academies. He died of a lipomyxoma of the shoulder joint in 1891.

Wiktor Feliks Szokalski was skilled in several languages, especially German and French, which he spoke fluently; he wrote numerous articles in those languages.

He published many important medical works in German and French journals and wrote books in the field of ophthalmology that were published in the German, French, and Polish languages.

The subjects of his scientific publications concerned nearly every field in ophthalmology. Furthermore, as an all-round physician with experience in general medicine, he published numerous articles on general diseases.²

Szokalski wrote the first Polish two-volume textbook of ophthalmology [Szokalski 1869] later translated into Russian.

A. SZOKALSKI'S PUBLICATIONS IN OPHTHALMOLOGY

In his important publications in German, Szokalski dealt with color vision (1842), limbus dermoid (1843), pterygium (1845), scrofulous ocular disease (1846), lens luxation (1846), psychogenic visual deterioration (1846), corneal opacifications (1846), corneal abrasion (1847), monocular diplopia (1847),

² Grzybowski A, Winiarczyk I. Ciekawe życie ojca polskiej okulistyki Wiktora Feliksa Szokalskiego (1811–1891) – w dwustulecie urodzin. [Interesting life of Wiktor Feliks Szokalski, father of Polish ophthalmology. In 200 anniversary of his birth] *Klin Oczna* [Polish Journal of Ophthalmology] 2011;113: 280-285.

³ Szokalski W (1869) *Wykład chorob przyrzadu wzrokowego u człowieka* [A lecture on diseases of the human eye]. vol. 1-2, Warsaw: Drukarnia Jozefa Ungra.

protective eye glasses (1848), ocular accommodation (1848), chronic ocular diseases (1848), influence of the fifth nerve-pair on vision" (1849), vision and cerebral disturbances (1854), papilloma corneae (1864), recommendations for cataract surgery (1864), traumatic orbital aneurysm (1864), malignant retinal glioma (1865), electrical-gymnastic treatment of eye muscle pareses (1865), spastic entropion (1872), and the treatment of inflammatory conjunctival diseases (1884).

Szokalski described new findings on color vision, scrofulous dyscrasia, psychogenic visual impairment, histological findings in corneal clouding, corneal papilloma, traumatic aneurysm, and malignant retinal glioma (retinoblastoma)

He reported his experiences in the treatment of pterygium with ligatures, of corneal inflammations, corneal spots, safety goggles, electric-gymnastic treatment in eye muscle pareses, spastic entropion, and conjunctival diseases.

Szokalski developed new theories, i.e., of monocular diplopia, ocular accommodation, and the influence of the fifth-nerve pair on vision.

Translations and analysis of essential parts of Szokalski's German publications (chronologically):

Articles on the color perception

Szokalski's ophthalmological works discussed the physiology and pathology of color perception, published as a monograph in German in 1842, after his publications on color perception in French between 1839 and 1841:

Contents:

Part One,

PHYSIOLOGY OF COLOR PERCEPTION

Szokalski, referring to the literature, stated that not only light causes brightness in the eye. Different stimuli may also give rise to light sensitivity in an eye, for instance compression of jugular veins in a dark environment may trigger many flashes of light and light spasms in the eye.

Color vision-producing causes:

1. As a mechanical influence, Szokalski mentioned that pressure on a closed eye in the outer lid margin may elicit a bright yellow spot in the other closed eye, followed by a blue spot that disappears after the eye is opened.

2. An electrical stimulus may cause a kind of flash in conjunction with the appearance of colors.

By touching the mouth with a zinc pole and simultaneously the forehead with a copper pole, a violet spot may appear in the eye.

3. Blood congestion, sympathetic stimuli of the eye or ocular inflammations may give rise to color perception.

4. The imagination may trigger the perception of colors. Szokalski quoted Goethe, who stated that when he remembered a flower, its image appeared immediately in his mind⁴. Szokalski mentioned that Newton identified seven rays in the solar spectrum. Since this important discovery, colors became measurable entities subject to mathematical principles.

Szokalski described doing the following experiments:

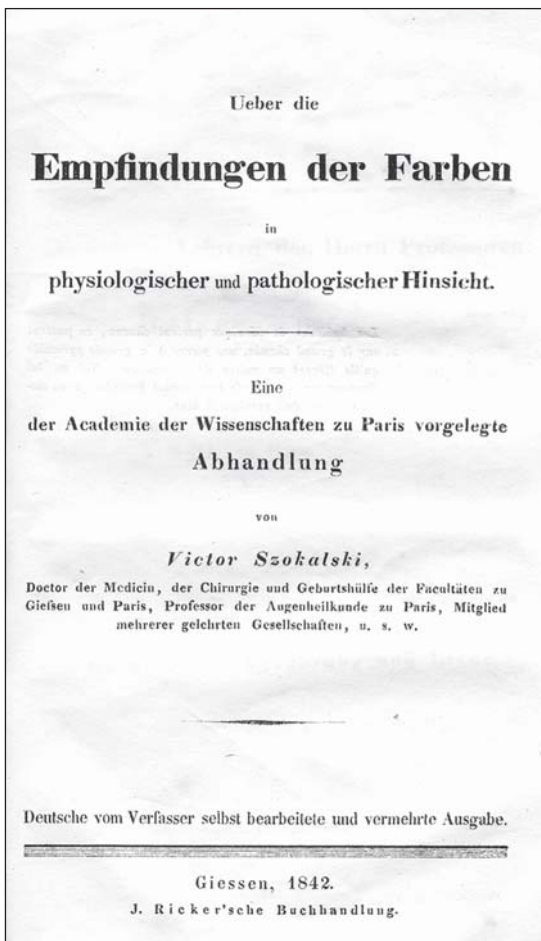
1st experiment: continuous viewing of an illuminated white piece of paper in front of a black background triggers a yellow color after a few seconds, then green, and later a blue color provided one keeps staring at the piece of paper.

2nd experiment: continuous viewing of a white screen exposed to sunbeams in a dark room, caused, after shielding the sunbeam, a change in the white color to an orange-colored gleam, brighter in the center, that changed shortly afterwards to a red circle surrounded by an increasingly broader one approaching the center. A violet circle then appeared that became smaller and darker.

3rd experiment: in this experiment, the opposite setup as in the second experiment, this occurred: after viewing a brightly-lit spot on a screen in a dark room, a sudden opening of the window shutter immediately caused the white light spots to disappear, followed by a black point appearing shortly afterwards that changed to green and later to yellow.

4th experiment: two screens, a white and a black one, were positioned side by side in a dark room. A light beam was directed onto the white screen, while the individual stared at the light spot. After the window shutter was opened, the person's view switched between the two screens. When viewing the black screen, color spots appeared in the sequence of the second experiment. When viewing the white screen, color spots occurred in the sequence of the third experiment.

Similar color perception may appear in case of a sunset in conjunction with a continuous view in the sun's direction followed by alternating views of a bright and a dark cloud.



Szokalski's translation of the 9 chapters on Color Perception published 1839/40 in vols.2 & 3 of the *Annales d'Oculistique*.

Wayenborgh Collection

⁴ pp. 5-7

Szokalski reported that he performed three of these experiments in a similar, but slightly different manner from Goethe's when the poet carried out his experiments on color sensations.

5th experiment: continuous staring at a yellow piece of paper on a white background for a certain time caused, after the paper was removed, a violet color perception where the yellow paper had been. Continuous staring at the yellow sheet of paper on a black background also caused the perception of violet after the paper's removal. However, the color of the image on a white background appeared darker than that of the image on the black background.

"Primitive" and consecutive color perception

Szokalski discussed "primitive" and consecutive color perception.⁵ The consecutive colors were called complementary colors.⁶ He argued that black means the complete inactivity of color perception, and the production of white refers to the greatest activity in the visual system. If one assigns number one to be white and zero black, the percentage of white in blue would be $\frac{1}{4}$, in red $\frac{1}{2}$, and in yellow $\frac{3}{4}$.⁷ By mixing the colors blue, red, and yellow, the result would not be white, but rather a color somewhere between white and black. Two colors located side by side influence each other. The eye keeps trying to perceive different colors individually, but a change takes place, a red strip of paper next to a blue one makes the red paper appear yellow and the blue one green. By means of a modification, the complementary color is created.⁸ Szokalski observed that complementary colors appear in both temporal and spatial dependency because they occur both after and concurrently with the "primitive" colors.⁹

Part two:

ON CONGENITAL DEFECTS IN COLOR PERCEPTION

In the second part of his book, Szokalski discussed the seldom-occurring achromatopsia, that is, an anomaly causing total insensitivity to colors, whereby the person has no perception of color. He considered this disorder in the first category of color perception disorders. Partial color recognition, however, he referred to as „chromatopseudopsia“¹⁰

According to the literature cited in Szokalski's book, a color-blind person was able to distinguish chromatic patterns by the various degrees of gradation between bright and dark forms because only white and black are distinguishable.¹¹

Concerning the second category of color perception disorders: Szokalski mentions individuals able to recognize some colors. He reported having observed only one person unable to identify blue out of 100 individuals with „chromatopseudopsia“.¹²

Heredity of color defects

Szokalski reported that congenital „chromatopseudopsia“ was often inherited¹³ and that it overwhelmingly affected men.

Part three:

THE PATHOLOGY OF COLOR PERCEPTION

Szokalski considered individuals able to recognize some colors but not discriminate them to be in the third category of color perception disorders. Szokalski reported on a man able to distinguish yellow from blue, bright blue from green, dark red and black. Such individuals confuse green¹⁴ with purple, orange with brown and indigo.

Dalton's color vision defect

Concerning the fourth category of color perception disorders: Szokalski classified individuals¹⁵ having difficulty recognizing the color red. He mentioned the color defect of the famous chemist and physicist John

⁵ pp. 11-14.

⁶ p. 16.

⁷ pp. 32-34.

⁸ pp 48, 49.

⁹ Szokalski described the phenomena of simultaneous and successive contrasts

¹⁰ p. 62.

¹¹ P. 64,65.

¹² p.68.

¹³ pp. 106, 107.

¹⁴ pp. 73, 74.

¹⁵ Dalton had protanopia

Dalton (1766-1844). Dalton had reported that he was able to identify white, green, and yellow, but confused purple, blue, and violet. Red was a shadow for him. Yellow, orange, and green were the same color for him. A red rose, a violet, or a geranium appeared blue to him.

Difficulty recognizing color nuances

Concerning the fifth class of color perception disorders; Szokalski mentioned individuals able to recognize five "primitive" colors (basic colors) imprecisely, and that they could not distinguish between color nuances. Szokalski examined a 33-year-old man in the clinic of Dr. Sichel in Paris in 1837. This man could identify yellow, blue, and red, but not green and violet. He mistook dark green for dark brown.¹⁶ He perceived no difference between light yellow and light green. A rose appeared bluish to him. During his life he had managed to memorize the colors of certain objects¹⁷

Discussion of the site of color defects

Szokalski mentioned the different theories concerning the origin of the „chromatopseudopsia“ disorder. He quoted John Dalton who thought that changes in the ocular vitreous body might be the cause of color perception disorders. Thomas Young (1773-1829) reported that every color has a corresponding fiber in the retina. Sir Brewster explained that the cause of „chromatopseudopsia“ is the retina's insensitivity to colored rays¹⁸ Szokalski thought that the failure to recognize colors may be attributable to a cerebral functional disorder.

Hemeralopia and nyctalopia

In addition, Szokalski described "congenital amblyopia" and addressed hemeralopia and nyctalopia^{19 20}

He concluded that both hemeralopia and „chromatopseudopsia“ are

¹⁶ In confusing red, orange, and green, the color deficiency is in the green area - typical of deuteranopia pp. 94-98.

¹⁷ pp. 118-123.

¹⁸ G. Holland emphasizes the various and confusing definitions over the centuries. Nowadays, the correct term for nyctalopia is night blindness, and for day blindness hemeralopia. G. Holland: *Mitteilungen der Julius-Hirschberg-Gesellschaft* 4 (2002), p. 131-147

²⁰ pp. 129-131.

congenital/hereditary disorders. Both defects are mainly transmitted by the female, with hemeralopia not occurring as often as „chromatopseudopsia“.²¹

Szokalski addressed "pathological amblyopia"; photophobia as excessive sensitivity to light, photopsia means the appearance of flames and sparks in the eyes, and metapropoptic perception is characterized by a change in the shape of objects. A vision impairment is associated with these phenomena²²

During Szokalski's life, hemeralopia referred to night blindness, but it now refers to day blindness. Szokalski reported that night-blind individuals may see rather well during the day but as soon as the sky becomes overcast, they no longer see well and during the night cannot see anything at all. These individuals are entirely dependent on light.

Szokalski VF. *Drei Beobachtungen aus der augenärztlichen Praxis, vorgetragen in dem Vereine der deutschen Ärzte zu Paris von dem Begründer derselben Dr. Victor Szokalski, Ärzte des 7. Arrondissements der Stadt Paris.*

Vierteljahresschrift prakt Heilkd 1846; 4: 18-29 ("Three observations in an ophthalmological practice, presented to the Society of German physicians in Paris, by the founder of this Society. Society of physicians of the seventh arrondissement in Paris", 1846) *Congenital corestoma of a peculiar species, confused with a syphilitic iritis*

Szokalski reported on an eight-year-old, weakly girl referred to him following the suspicious diagnosis of a syphilitic ocular disease. Hers had been a premature birth. A harelip was operated on in her first days of life. She had several ulcers in her mouth, the submaxillary glands were swollen, her scalp revealed purulent, incrustated spots. The inflammatory ocular disease was treated with antiphlogistic agents because of suspected syphilitic disease. Szokalski observed severe photophobia and distinct swollen eyelids when he examined the girl for the first time. Szokalski diagnosed a scrofulous dyscrasia and not a syphilitic disease. The girl exhibited

²¹ P. 138.

²² pp. 142, 143.

indurated cervical glands, odontopathy, thick upper lips, a thickened abdomen, and was bandy-legged with exostoses. Szokalski ordered extract of belladonna, gray mercuric ointment on the temporofrontal areas, laxatives, and he applied leeches close to the ears. The child had to remain in an airy, semi-illuminated room. After three weeks, the girl was able to open her eyes. Szokalski diagnosed a distinct miosis, and the cornea was cloudy with small vessels at the limbus.²³ Szokalski presumed a congenital iris anomaly and observed no signs, of syphilis. The pathological changes were compatible with scrofulosus.²⁴

A liquified, intracapsular cataract in the ocular anterior chamber

A 50-year-old man with a 20-year-old left-sided cataract was examined by Szokalski. Several hours after a fall, the patient noticed a dull tenderness in his left supraorbital area extending to the left face region. Szokalski's examination revealed a flat, lens-sized, vertical oval bladder in the anterior chamber of the left eye. The anterior chamber was completely filled up by the bladder. The iris was dislocated posteriorly, funnel-like. Szokalski diagnosed a cataract luxated into the anterior chamber.²⁵ The patient underwent blood-letting, drastic purgatives and foot baths. In addition, the eye was treated with bandages, and soaked in belladonna solution. However, as the conjunctiva developed increasing redness, corneal cloudiness, and an, intense frontal headache, Szokalski decided to operate on the eye, making a corneal incision at the limbus. The anterior content then emptied spontaneously and the lens capsule was removed after he had excised the parts of the capsule fused with the iris., The patient's pain disappeared after surgery and the intraocular hemorrhage was absorbed, however,²⁶ the eye was completely blind thereafter.

Amblyopia due to an unfulfilled sexual desire

Szokalski reported on a 25-year-old woman who had been suffering from worsening vision for several years. She reported on exhaustion, fatigue in her legs, memory prob-

lems, and sleeplessness. She had become sensitive to light, had pain in the supraorbital regions and photopsia. She felt she was under a lot of stress.²⁷ Her bad health had existed for about three years, starting after she got married. Szokalski examined her gynecologically, found that she was still a virgin, and that her vagina was extremely constricted. This finding explained her poor psychological and generally problematic state of health. After gynecological therapy, the patient recovered. Several weeks later she became pregnant. Both her vision and general health became much better.²⁸

Szokalski VF. *Von den Trübungen der Hornhaut in histologischer Hinsicht mit Bezug auf Augenpraxis*. Arch Physio Heilkd 1846; 5: 183-237

("The corneal cloudiness with regard to histological findings, in relation to the eye practice"; 1846)

*Szokalski's publication in French concerning this topic*²⁹

"The histology of corneal cloudiness in ophthalmological practice" (1846)

Corneal anatomy and pathology

In the first chapter of his comprehensive article, Szokalski reported on various corneal layers and pathological corneal changes. He divided the corneal tissue anatomically into three layers: the outer, middle, and posterior³⁰ The outer leaf of the cornea ("Conjunctiva corneae"³¹) consisted of several epithelium layers.³¹ In this upper corneal layer, the superficial old layers gradually drop off and are replaced by deeper layers. Szokalski reported his observation in a patient who had had a superficial corneal injury; he observed circumscribed corneal cloudiness that disappeared completely after a few days.³² The epithelial cells are in a permanent cycle in which the old cells are sloughed off and new cells grow. Inflammations cause superficial corneal spots called

²³ pp. 19, 20.

²⁴ P. 22.

²⁵ p. 23.

²⁶ pp. 25, 26.

²⁷ P. 26.

²⁸ pp. 27-29..

²⁹ Szokalski VF. Recherches anatomiques sur la nature du staphylome de la cornée. Gazette Méd de Paris 1847; 2: 488-489

³⁰ p. 184.

³¹ p. 185.

³² p.186.

"nephelia"³³. Under the microscope he noted that the epithelial cells in the nubeculae were small, concentrated, and compact, and cohering closely to neighboring cells.³⁴ Szokalski reported the findings in an old woman with a large corneal ulcer due to "corneitis". He had examined her and extensive corneal anomalies while an assistant ophthalmologist six years previously at Sichel's clinic in Paris. She recovered completely (with a clear cornea and no treatment) four years later.³⁵

Staphylomatous changes

This disease is called total corneal staphyloma in case of total corneal clouding. Using a microscope with 200 x magnification he detected a small excised staphyloma, Szokalski recognized that the epithelial slice revealed fibers arranged like a "paternoster". He noted a thickened fibrous epidermic layer, occupying almost the entire corneal area and corneal thickness.³⁶ He observed hypertrophy with epithelial degradation in a staphyloma due to corneal inflammation like those that can occur in ophthalmia neonatorum. "Organically altered" deposits can be found between corneal lamellae in hypertrophic areas with indurations and thickening, appearing as cartilaginous or lardaceous masses. Inflammation-caused staphylomas often reveal adhesions between the iris and cornea.³⁷ The lens can also change due to corneal inflammation.

"Xerosis conjunctivae" and scrophulosis

Szokalski reported on another disease, namely „Xerosis conjunctivae“ or conjunctival cuticularization. In such a case, the cornea is as opaque as if it had been covered in a layer of grease. The cornea appeared lusterless, dull and grayish-yellow, totally opaque and with a dry, parchment-like covering. Under microscopy, white, hull-like, squamous epithelial changes with atrophic cell nuclei of conglomerated and packed epithelial cells appeared. In contrast to a staphyloma with a closely connected, thick layer, in xerosis, he detected dry elements from flaplike displacement, because some pieces of epithe-

lium had burst.³⁸ Szokalski reported on a girl with scrofulosis who exhibited a predisposition for bilateral lid entropion, similar to her father, with intense photophobia and blepharospasm due to chronic conjunctivitis, a distinct pannus and incipient staphyoma in one eye. The other eye revealed corneal xerosis³⁹

Pathological findings in chronic corneal inflammations

Szokalski divided the epithelium of chronic corneal inflammations into two forms: those with a pannus and those with a pterygium. A pannus is caused by vascularization, leading to increasing redness. An increasing carneous or spongy granulation with red brown color was referred to as "fungus". Pannus-like clouding is often found in catharralic ophthalmias in the upper corneal half. There is a more or less marked transverse line demarcating the upper pannus and distinguishing it containing from the clear lower part of the cornea.⁴⁰ A pterygium consists of hypertrophic tissue.⁴¹ There are different kinds of such changes: pterygium membranaceum or pterygium tenue, which differs from pterygium crassum, carnosum, and the pterygium tendinosum, and pterygium vasculare. The pterygium tenue grows lengthwise with few conjunctival vessels, while a pterygium crassum is thick and grows lengthwise. A cell-like or fibrous appearance indicates a pterygium celluloseum or pterygium tendinosum, respectively. A pterygium vasculare carnosum is highly vascularized.⁴²

Ocular foreign bodies

Szokalski lived in a neighborhood of Paris where more than 20000 gold-, copper-, and steel workers lived. He often had to remove corneal metal splinters. Among his hundreds of patients he always only noticed iron splinter injuries. Other splinters injuring the conjunctiva caused severe ophthalmia, similar to rheumatic ocular inflammations, which could lead to false diagnoses because some doctors had presumed rheumatic disease in such cases, but later a metal splinter was detected as causing the inflammation.⁴³

³³ Nephelia mean small clouds or nubeculae

³⁴ p. 187.

³⁵ P. 188.

³⁶ p. 189.

³⁷ p. 191.

³⁸ pp. 192, 193.

³⁹ p. 194.

⁴⁰ pp. 202, 203.

⁴¹ p. 205.

⁴² p. 206.

⁴³ pp. 208, 210, 211.

After an iron splinter had been removed, ferric oxide residue in the corneal tissue was found. To remove it, some physicians had tried treating with low concentrations of sulphuric acid in eye salve. However, that had caused marked ocular irritation. Szokalski recommended the mechanical removal of the cloudy foreign body areas. He also reported on corneal spots caused by treatment with lead oxide or sulphuric acidic zinc oxide in eye lotions. These solutions had been used to treat corneal ulcers. Lead and zinc particles accumulated deep within the ulcers and had triggered permanent corneal spots. Szokalski warned against the use of eye salve containing such substances.

Anatomy and physiology of the cornea

In the 2nd chapter, Szokalski described the anatomy and physiology of corneal tissue. He reported on fibrous bundles in the tissue beginning in the sclera, expanding to corneal center. Close to the sclera at the limbus, fibers broke into two or more branches, appearing like nets. Between fibrillary small leaves, he observed numerous cells filled with hyaline liquid. He reported corneal swelling leading to opacification, mainly in conjunction with very excessive and rapidly increasing eye pressure; but in contrast, when the pressure rises slowly as in hydrophthalmia, the cornea will remain clear. Szokalski also emphasized the fact that the refraction power is predominantly caused by the transit of light rays through the air to the cornea and much less by the lens curvature.⁴⁴

The importance of the cornea's nerve supply

Szokalski emphasized the importance of the nerve supply because opacification occurs after the experimental severing of the fifth cranial nerve in an animal, and after the superior cervical ganglion is destroyed.⁴⁵ Experiments in rabbits had shown that after cutting the fifth cranial nerve, corneal sensitivity disappeared. A few hours after surgery, the pupil dilated, but still reacted to light. Central corneal opacification began on the second postoperative day, extending over the entire cornea. In addition, the conjunctiva and lids became red and the Meibomian glands' secretion increased. From the eighth

to tenth day after surgery, the cornea became milky white and leukomatous. The pronounced conjunctival redness remained⁴⁶ During the long-term follow-up of a rabbit that survived eight weeks, corneal areas cleared up, but corneal sensitivity remained absent.⁴⁷ In addition, Szokalski mentioned that after cutting the trigeminal nerve, corneal opacification only occurred after injury to the semilunar ganglion Gasseri. But after cutting nerve fibers between the ganglion and central cerebral areas, no corneal cloudiness was detected, however corneal sensitivity was gone. Magendi had also carried out such experiments.⁴⁸

Szokalski also carried out experiments on rabbits, cutting through the superior cervical ganglion.⁴⁹ and noticed that changes in the eye after this procedure were less pronounced after a sympathetic lesion than when the trigeminal nerve had been cut in the vicinity of the ganglion Gasseri.⁵⁰

Corneal inflammations

Corneal inflammations revealed canals overflowing with blood. The serum seeped into the parenchymal tissue, later causing thickening and cloudiness. The cornea appeared milky white. As inflammation worsened, pus corpuscles were observed accumulating in an exudate from which a corneal abscess developed. The loss of fibers and corneal tissue was followed by ulcer development, and pus could be excreted anteriorly or posteriorly, with the appearance of a hypopyon. Pus may decrease within the corneal tissue, becoming dry via absorption of the serum, and the pus corpuscles may merge into a yellow mass. In case of a granular exudate consisting of albumen and fibrous tissue lying between corneal lamellae, initial grayish cloudiness may gradually become white, resulting in a leucoma. The fiber displacement via tissue accumulation can become so compact that it resembles fibrous cartilage called "Albugo". Such changes involving the accumulation of calcium salts, mainly in very old staphylocomas, may turn into a kind of petrification or may appear as

⁴⁶ pp.215, 216.

⁴⁷ p. 217.

⁴⁸ p. 219.

⁴⁹ p. 220.

⁵⁰ p 221.

⁴⁴ p. 212.

⁴⁵ p. 214.

a type of ossification. A pearl-like appearance is referred to as *macula margaritacea*.

Treatment of corneal inflammations

Corneal inflammations were treated with antiphlogistics. This was done to reduce the blood congestion („depletiva“), Remedies were applied to relieve congestion („revulsiva“) or prevent congestion („repercussiva“).⁵¹

Szokalski argued that the best blood depleting therapy was blood-letting, which he considered the sole remedy a keratitis. Szokalski carried out leech therapy only in exceptional situations. In addition to blood-letting, he prescribed mustard paste as a kind of revulsion remedy (a mixture of mustard flour and warm water) for the lower extremities and stimulating foot baths. Szokalski used narcotics and cold therapies as repellent remedies („repercussiva“). Rubbing with anesthetic agents in the forehead region and temples the irritated nerves that had caused congestion. Cold compressions caused and the intense cohesion of corneal tissue and prevented blood congestion.⁵²

Szokalski ordered to encourage salivation large doses of „Kalomelas“ or salves containing gray mercuric salt. To intensify salivation, he used cotton pads dipped in horseredish, „radix pyretri“ or clove oil that he placed between the gingiva and upper lip close to the stenonic ductus. The idea of increasing salivation was justified by the fact that the salivary glands are located close to the eyes, and because the two organs share arteries. The activation salivation makes a strict diet necessary.⁵³ An accumulation of foreign substances in corneal tissue was treated by eye salves, fumigation, and application of several ointments. These should soften and liquefy effused substances to facilitate their removal from the cornea. In case the effect is insufficient, he maintained that electricity be used to increase the effect of these remedies by influencing the trigeminal nerve on the cornea.⁵⁴

Changes in Descemet's membrane

In the third chapter, Szokalski mentioned the opacification of Descemet's membrane. The corneal posterior and anterior

surfaces of the iris can become inflamed simultaneously. The ciliary arteries supply Descemet's membrane before entering the iris. When the iris is inflamed, small epithelial blisters on Descemet's membrane become opaque. Isolated inflammation of Descemet's membrane is very rare.⁵⁵ Descemet's membrane can be destroyed by ulcers on the corneal inner surface due to an abscess. This membrane is not replaceable. Of all the corneal tissues, he considered Descemet's membrane to be⁵⁶ the layer that resists putrefaction longest.

Szokalski VF. *Das Abschaben der Hornhautflecken*. Arch Physiol Heilkd 1847; &: 638-641 (Szokalski's publication from Paris)⁵⁷
“Abrasion of corneal spots” (1847)

Szokalski reported on a man blind for three years due to corneal opacification. The right cornea revealed grayish-yellow clouding. The left eye was slightly less opaque, thus the patient could see a bit with that eye. The opacification had developed due to a corneal inflammation lasting many months. Szokalski assumed that the deeper corneal layers would also be turbid; he was very surprised to notice that after abrading the superficial corneal layer, the cornea became brighter in some parts. After the total corneal abrasion of superficial opaque tissue, the central corneal parts became clear, but an opaque corneal ring on the periphery remained. The patient could see again with his right eye postoperatively. However, he had double vision in this eye that was attributed to remnants of opaque corneal tissue. Szokalski described this patient's eye after his successful surgery to physicians at the Academy of Medicine in Paris on April 14th. He also operated on the patient's left eye which suffered a stronger inflammatory reaction than had occurred⁵⁸ after the first operation on the right eye.

⁵⁵ pp. 234, 235.

⁵⁶ p. 237.

⁵⁷ Szokalski's publications in French concerning this topic:

Szokalski VF. *De l'abrasion de la cornée*. L'union Méd (Paris) 1847: 591.

Szokalski VF. *Abrasion de la cornée transparente*. Bull Soc Chirurg Paris 1852; 3: 504-506

Szokalski VF. *Compte rendu de trente-deux cas d'abrasion de la cornée transparente*. Gazette Méd Paris 1854; 24: 232-233

⁵⁸ pp. 640, 641

⁵¹ pp. 226-228.

⁵² p. 229.

⁵³ p. 230.

⁵⁴ p. 231.

Szokalski operated when the patient was in a sitting position with the head leaning against an armchair. The eye was kept open via a Kelly-Snowden lid holder during the procedure. Via finger-pressure on the eye's inner lid corner, the eye could be immobilized.⁵⁹

Szokalski VF. *Das Doppeltsehen mit einem Auge*. Vierteljahresschrift prakt Heilkd 1847; 2: 22-44 Vorgetragen im Vereine deutscher Ärzte in Paris.⁶⁰ ("Monocular double vision"; 1847 Presentation at the Society of German physicians in Paris)

In his thesis in Paris in 1839, Szokalski⁶¹ addressed the topic of unocular diplopia. He had noticed that double vision may disappear after belladonna extract is dripped into the diseased eye. A convex lens enlarges the distance between the two unocular images, a concave lens decreases the distance. Diplopic eyes usually are myopic.⁶² Double vision may occur in connection with diseases of the retina, choroid, or lens. He argued that the origin of double vision is usually in the eye's optical apparatus.⁶³ A beginning cataract may trigger double vision or polyopia, particularly in soft cataracts or in case of wedge-shaped changes to the lens's cortex.⁶⁴ Corneal opacifications and changes to the lens curvature can also cause unocular diplopia.⁶⁵ (Szokalski differentiated between forms of diplopia, e.g. "idiopathic" diplopia may occur after corneal changes, particularly those caused by anatomical defects. "Symptomatic" diplopia may develop in the cornea if a change in refraction has developed, for instance with choroidal disease. The recommended treatment of monocular diplopia⁶⁶ involved the wearing of concave eye glasses.

Szokalski VF. *Über die hygienische und therapeutische Anwendung der Schutz-*

⁵⁹ p. 643.

⁶⁰ Szokalski's publication in French concerning this topic: Szokalski VF. *Lettre sur la diplopie uniloculaire* Ann d'Ocul 1840; 3: 150-155

⁶¹ p. 23.

⁶² pp. 25, 26.

⁶³ p. 27.

⁶⁴ pp. 30, 31.

⁶⁵ p. 34.

⁶⁶ pp. 42, 43.

brillen und der optischen Gläser. Vierteljahresschrift prakt Heilkd 1848; 6: 139-172 ("On the hygienic and therapeutic use of safety goggles and optical glasses", 1848)

Protective spectacles

Szokalski called glasses with protective lenses "conservation" spectacles because they protect the eyes from harmful influences by foreign bodies or dazzling light.

He recommended colored and colorless glasses. The glasses were fixed in wide rings and fastened by a piece of leather. Szokalski emphasized that employees in certain professions such as metalworkers, locksmiths, blacksmiths, and stonemasons are at a particular risk because their jobs often entail working with small foreign bodies that can be hurled against the eye at great force. "Conservation" glasses are unsuitable for these professions because of their fragility. He therefore recommended "fine glimmer discs" and small "white horn blades" that could also be used in chemical laboratories. For people who are easily dazzled by bright lights, he prescribed colored protective glasses; he also recommended blue and green glasses. He claimed that blue glasses are the best protection against dazzling light.⁶⁷

Glass size is important because if they are small, light can enter the eyes sideways.⁶⁸ Colored protective glasses should predominantly be used by people with that are highly sensitive to light, particularly those with photophobia due to anterior eye inflammation.⁶⁹

Szokalski emphasized the basic principle that glasses in front of patients' eyes must be positioned so that the visual axes are in precise alignment with the eye's center.⁷⁰

Concentration glasses

Szokalski referred to convex and concave glasses as „concentration glasses“ because light rays approach each other in these glasses.⁷¹ He differentiated between convex glasses used to correct presbyopia and those to correct aphakia. To correct presbyopia earlier, glass strength had been prescribed according to a patient's age using Mackenzie's table. But Szokalski emphasized that the

⁶⁷ pp. 140-142.

⁶⁸ p. 143.

⁶⁹ p. 144.

⁷⁰ P. 147.

⁷¹ p. 153.

strength of a prescription should not only be made according to a patient's age because individual factors need to be considered. He recommended that glasses be individually prescribed, not schematically.⁷² He called concave glasses „dispersion“ glasses. They make objects smaller and disperse light. He also found that the numbering of concave glasses to determine focal length differed between Germany and England.⁷³

As Szokalski lived close to a reformatory, he often examined young people with visual impairments, most of whom were myopic. From 1834 to 1845, he diagnosed 89 pupils who were myopic (of a total of 807 at the «Collège Charlemagne»⁷⁴). In case of monocular diplopia, he prescribed dispersion⁷⁵ glasses that the patients found comfortable.

Szokalski VF. *Das Anpassungsvermögen des Auges vom pathologischen Gesichtspunkte aus betrachtet*. Arch Physiol Heilkd 1848; 7: 695-709

(“The adaptation of eyes, regarded from the pathological point of view”, 1848)

Szokalski's theory of accommodation was the following:

By fixating on a close object, the straight eye muscles that are attached on a tendonous ring around the cornea contract. Due to this muscular contraction, the globe's posterior is pushed backwards against orbital fatty tissue. The globe's posterior is flattened out by the pressure. Due to the globe's backward movement, the vitreous body is pushed forward against the lens that also moves forward. As the lens moves forward, the distance from the retina becomes enlarged, while the lens' convexity increases, causing an increase in light refraction. The corneal curvature also increases due to contraction of the straight eye muscles.⁷⁶ Szokalski described his observation that in case of a complete ophthalmoplegia the eye becomes hypermetropic, and accommodation is no longer possible. With paresis of the oculomotor nerve, accommodation paresis is less pronounced.⁷⁷ He concluded:

⁷² p. 161.

⁷³ p. 163.

⁷⁴ pp. 165, 166.

⁷⁵ p. 171.

⁷⁶ pp. 700, 701.

⁷⁷ p. 704.

1. accommodation involves forward movement of the vitreous body accompanied by anterior movement of the lens and intraocular fluid. Optical conditions change after such movements;

2. the forward movement is caused by coordinated activity of the straight eye muscles, and

3. the pupillary movements that accompany this accommodative action depend on this sequence of events.

Szokalski VF. *Briefe über die Behandlung chronischer Augenentzündungen*. Allgem Med Cental-Zeitung 1848; 17: 170-171; 178-183; 186-191; 194-198

(“Letters on the treatment of chronic ocular inflammations”, 1848)

Szokalski recommended the following procedures for chronic eye inflammation:

1. any harmful irritation should be avoided,

2. the influx of blood to the inflamed eye must be reduced, and

3. resorption in the inflamed eye should be encouraged.

4. The irrigation of ocular nerves should be reduced

Reducing the blood supply

To decrease blood congestion, the quantity of blood should be reduced („depletio“) or the blood stream diverted into another organ (“revulsio”).

Astringent remedies should be undertaken to reduce the blood supply to the diseased tissue (“repercussio”). Deposits in the diseased tissue should be removed. Therefore, a special diet is necessary, as well as purgatives, salivating agents and „diaphoretics“. To relieve the irritated nerves, alleviating medication should be given. Szokalski was convinced that blood letting was important because it acted as an anticongestant and supported resorption.⁷⁹

Ocular protection

Irritated eyes should be protected from light to minimize photophobia. The eye should be closed with a bandage. Szokalski preferred using a bandage for this purpose

⁷⁸ p. 709.

⁷⁹ pp. 170, 172.

after having cleaned the eyes. This was particularly helpful in children with scrofulous photophobia and blepharospasm.

Blood-letting for ocular inflammations

Szokalski was convinced that blood-letting for acute ophthalmias was one of the best remedies. In chronic ocular inflammations he recommended – if there was no contra-indication – blood-letting of small amounts of blood, every four days. Only in “plethoric” persons did he recommend major blood-letting, which was done from the patient’s foot. He argued that treatment with leeches could replace blood-letting, but that it is costly, awkward, and the outcome uncertain.⁸⁰ Apart from blood-letting, scarification treatment with a cupping instrument was helpful. These “transient revulsive agents” were prescribed for diverting the blood flow into other organs, for instance via “dry cupping instruments”, stimulating foot baths, mustard plasters, blistering, or purgatives and diaphoretics, and agents promoting salivation (sialogogues).⁸¹ He also mentioned treatment with “hair ropes” on the neck to be beneficial, mainly for treating inflammation of the choroid, iris, and anterior lens capsule.

Stimulation of the salivary gland

In the following chapter on “revulsion” by encouraging natural secretions, Szokalski recommended laxatives and treatment with agents that increase salivation. The idea was to stimulate the salivary gland, as being so close to the eyes, they might affect them. As the eyes and salivary glands share the same arterial supply, perhaps an increase in saliva could relieve ocular inflammation. He believed this treatment would be beneficial in case of iritis or parenchymatous keratitis.⁸²

Treatment with cold water

Szokalski considered cold therapies for ocular inflammation to be important because flow of blood to the eye might be minimized by cold. He recommended laying compresses soaked in cold water on the diseased eye four to six times a day. Szokalski re-

placed the cold compresses with a pig’s bladder filled with cold water hung from the ceiling that touched the sitting patient’s eye, and taking pressure off it. He obtained good results with this treatment.⁸³ For treatment with cold water eye rinses, Szokalski recommended irrigation through a tube. The cold water pail flowed from a bucket filled with cold water suspended from the ceiling through a long narrow tube into the diseased eye. Those eyes affected by blepharitis, keratoconjunctivitis, with chronic corneal ulcers, and those developing from varicose ulcers responded best to this treatment.

Treatment with argentum nitricum

Treatment with astringents was carried out to relieve conjunctival inflammation, catarrhs, and blenorrhagic inflammation. As astringents, Szokalski recommended silver nitrate that had proven effective in patients with sarcoous granulation and choroid ulcer secretions.⁸⁴ He experienced better results in treating conjunctival granulation with silver nitrate than with copper sulfate. He reported that while working as assistant physician in Dr. Sichel’s clinic from 1838 to 1940, he treated several hundred patients with sulfuric acidic copper, but this treatment caused strong irritation in many patients. He later rejected this treatment.⁸⁵

Additional remedies

Treatment with narcotic remedies was carried out by spreading acetic morphine ointment onto bandages when covering a wound. This greatly relieved the pain.⁸⁶ To reduce retinal irritation in patients suffering from photophobia, Szokalski recommended that belladonna be rubbed onto the forehead or temples. He believed that belladonna extract helped relieve the sensitive retina.⁸⁷

Szokalski VF. *Ueber den Einfluss des fünften Nervenpaares auf das Sehvermögen*. Arch Physiol Heilkd 1849; 8: 317-349 (“The influence of the fifth nerve-pair on vision”, 1849)

⁸⁰ P. 178.

⁸¹ pp. 179, 180.

⁸² pp. 185, 186.

⁸³ pp. 187, 188.

⁸⁴ pp. 189, 190.

⁸⁵ p. 191.

⁸⁶ pp. 193, 194.

⁸⁷ p. 195.

The fifth nerve-pair mediates the sensitivity of external and internal ocular changes.⁸⁸ Szokalski explained that both the retina and the “fifth nerve-pair” are necessary to see something. The „fifth nerve-pair“ regulates spatial perception and supplements Retinal function. Szokalski’s idea was that the pictorial impression arises through the retina, and that the “fifth nerve-pair” is necessary to mediate spatial vision.⁸⁹ It is therefore required to visually capture movements in space. The “fifth nerve-pair” is important to assess size, direction, and position⁹⁰ as well as to assess distances between objects.⁹¹

Szokalski VF. *Von den unmittelbaren Sehorganen mit Rücksicht auf die Cerebralstörungen der Gesichtsfunktion*. In: Vierteljahrschrift Prakt Heilkunde (Hrsg. Med. Fakultät Prag, Redaktion J. Halla, J. v. Hasner) 1854; 1. Bd. Verlag Karl André Prag; S. 65-108
 (“Visual organs in relation to cerebral visual function disorders”, 1854)

The importance of eye muscles for visual perception

Szokalski began by explaining visual impressions and comparing seeing and feeling as passive processes, whereas but perceiving and touching are active ones. A sensation only can arise if the muscles contract intentionally. The perception of direction is essentially mediated by the eye muscles in contraction. Szokalski claimed that the eye muscles’ contraction is essential to perceiving directions in space. Thus the spatial conception of “vertical” and “horizontal” in relation to one’s own body and of the direction of the visual axis may be attributed to the muscles’ state of contraction. Spatial perception is conducted to the brain or “sensorium” via the trigeminal nerve and its anastomosing branches in all the muscles necessary for movement. An adjustment⁹¹ mechanism is necessary to assess distances. When an image appears on the retina, an eye muscle contraction and attentive response by the visual axis direct it exactly to the object being perceived. The signal to concentrate on an object depends on the individual’s atten-

tion. The retina conducts the optical while the “fifth nerve-pair” relays spatial conditions the brain.⁹²

The central and peripheral oculomotor system

In his book on the anatomical cerebral visual pathway, Szokalski reported according to the knowledge at his time.⁹³ He also described the pathways in the ocular motor system.⁹⁴ He also addressed the coordinating influences of movements in the cerebellum and pons. He distinguished between intentional and instinctive movements, and dealt with ocular reflex movements:⁹⁵ the intentional ones⁹⁶ and those that are instinctive.⁹⁷ He referred to the eye muscles as “tools” that are necessary to coordinate a cerebrally-elicited, intentional eye movement in combination with the retinally-mediated visual impression.⁹⁸ He ended his explanations with the sentence “...to examine with the eyes, to view or look means to ‘touch’ with the eyes, to move intentionally, or to perceive movement”. (*“Mit dem Auge untersuchen, blicken oder schauen, heißt mit dem Auge tasten oder absichtlich bewegen oder Bewegungsempfindungen wahrnehmen.”*)

Szokalski VF. *Papilloma corneae*. *Klin Monatsbl Augenheilkd* 1864; 2: 326-328 (“Corneal papilloma”, 1864)

Szokalski’s⁹⁹ publication in French concerning this topic

A 40-year-old man revealed globular formation on the left cornea, the half of which lay on the conjunctiva. It was a firmly attached to the cornea, the globular tumor was soft, red, and immobile, with a lustrous surface. Examination with a magnifying glass¹⁰⁰ revealed numerous “unfolding leaves”. Thickened blood vessels were visible between the outer corner of the eye and the tumor

⁸⁸ p. 322.

⁸⁹ p. 338.

⁹⁰ p. 349.

⁹¹ pp. 68, 69.

⁹² p. 70.

⁹³ pp. 70-77.

⁹⁴ pp. 77-82.

⁹⁵ pp. 82-86.

⁹⁶ pp. 86-91.

⁹⁷ pp. 91-99.

⁹⁸ p. 99.

⁹⁹ Szokalski VF. *Papilloma de la cornée*. *Ann d’Oculist* 1865; 54: 60-63

¹⁰⁰ p. 326.

base. Szokalski removed the growth surgically. Histology revealed that the tumor consisted of cylindrical outgrowths bending out like leaves in a palm from the center to side. The individual cylindrical sprouts consisting of compressed spindle cells with each surrounded by a vessel.¹⁰¹ Szokalski diagnosed a corneal papilloma.

Szokalski VF. *Aneurysma traumaticum diffusum in der Augenhöhle*. Klin Monatsbl Augenheilkd 1864; 2: 427-431; Vierteljahresschrift prakt Heilkd 1865; 22: 91—92 (“Diffuse traumatic orbital aneurysm”, 1865)¹⁰²

Szokalski had treated a diffusely growing, traumatic orbital aneurysm in a 50-year-old man in the Warsaw Clinic. While chopping wood, a piece of wood flew against his left temple. His temple injury had been treated, but he still suffered pain. Weeks later, he presented an increasing exophthalmos in the left eye which deviated inward and forward with reduced mobility. His vision was preserved, but the patient suffered from annoying diplopia. Pulse-synchronous swelling had developed between the upper outer orbital margin and the globe. In addition, at the left temple, pulse-synchronous swelling also appeared. By compressing the common carotid artery’s trunk, the swelling in both locations stopped pulsating. Szokalski diagnosed a communicating traumatic diffuse aneurysm in the orbit and temple.¹⁰³ The aneurysm was subjected to finger compression on the common carotid artery by the nursing staff, changed every 20 minutes. This permanent compression was carried out for 56 hours. However, the swelling was not affected. The patient refused an operation. However, the painful tumor had increased in size after three months, and the eye had gone blind in the meantime, making surgery necessary; the patient then agreed. A ligature of the carotid artery was done under chloroform. On the fourth postoperative day, the temporal artery pulsated again, but the tumor remained hard and immobile. The pain diminished six weeks later and the

¹⁰¹ pp. 327, 328.

¹⁰² Szokalski’s Publication in French concerning the topic: Szokalski VF. Aneurysme traumatique diffus de l’orbite. Ann d’Oculist 1865; 54: 116-119

¹⁰³ pp. 427, 428.

tumor became soft and smaller.

Later, an aneurysm in the iliac artery, together with pain in the right hip occurred. An aneurysma as large as a pigeon egg on the crest of the hip bone was diagnosed. The patient had a disposition for aneurysms because of “lax” arterial walls (pp. 430, 431).

Szokalski VF. *Glioma malignum retinae*. Klin Monatsbl Augenheilkd 1865; 3: 396-404 (“Retinal malignant glioma”, 1865)

A 2½-year-old boy presented with a fist-sized tumor having the characteristic signs of a medullar sarcoma of his right orbit. The left eye with an enlarged pupil demonstrated node-like, yellowish-white tumor mass containing numerous blood vessels tight behind the lens and extending to the ora serrata.¹⁰⁴ The left eye’s visual field was severely restricted. The right orbital tumor was removed surgically. The optic nerve was thickened, and the retina, choroid, lens and vitreous body were absent.¹⁰⁵ Histology revealed that the tumor consisted of “free kernels and cells”; the spindle-shaped cells were set in rows in some places. The tumor corresponded to a neuroglioma or glioma, as Virchow had called it, as there proliferating neuroglia.¹⁰⁶

Szokalski VF. *Von der electrisch-gymnastischen Behandlung der Augenmuskelparesen*. Klin Monatsbl Augenheilkd 1865; 3: 226-236 (“The electrical-gymnastic treatment of eye muscle pareses”, 1865)

Four patients with oculomotor palsy were treated by Szokalski.¹⁰⁷ He carried out faradization of individual paralyzed eye muscles.¹⁰⁸ He then recommended gymnastic exercises for eye muscle pareses, carried out with prismatic glasses. Double vision occurred when the head was turned in a certain direction; the double image would be unified by moving the head in one direction and doubled again by moving it in the opposite direction. The patient’s specific gymnastic

¹⁰⁴ pp. 396, 397.

¹⁰⁵ pp. 398, 399.

¹⁰⁶ pp. 399-401.

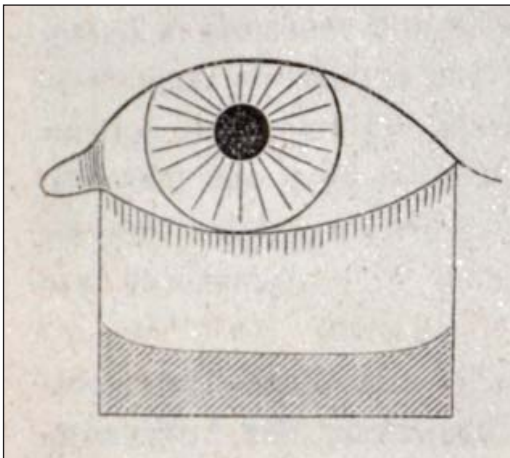
¹⁰⁷ p. 226.

¹⁰⁸ p. 228.

exercises made it possible to reduce the distance between the double images, and the paresis was minimized.¹⁰⁹ These exercises for treating paretic eye muscles also were carried out via day-long training sessions with Liebreich's ophthalmoscope.¹¹⁰ Szokalski designed a scale of angle degrees with a lengthening measuring instrument that he used to measure the extent of strabismic deviation.

Talko J. *Entropium spasticum operiert mittelst einer neuen von Dr. Prof. Szokalski angegebenen Methode*. *Klin Monatsbl Augenheilkd* 1872; 10: 25-29 ("Surgery newly developed by Professor Dr. Szokalski for spastic entropion", published by Joseph Talko, 1872)

The surgical method for treating spastic entropion, newly described by Szokalski, consisted in excising a somewhat square-shaped lower lid flap. The flap's size matched the lower lid's length (*see illustration*). After suturing the surgical wound, Jozef Talko mentioned that the entropium had disappeared in his surgically-treated patient.



Spastic entropium operation. Drawing by Szokalski in Klinische Monatsblätter, 1872, Vol.10

Wayenborgh Collection

Szokalski VF. *Ueber die Krankheiten der Conjunctiva und deren Behandlung*. In: Bericht über die augenärztliche Section der IV. polnischen Naturforscher- und Ärzte-Versammlung (Posen, Juni 1884.- Ksiazko jubileuszowo 1884, p. 362; *Centralbl Augenheilkd* 1884; 8: 403.

"On the treatment of conjunctival diseases". Report at the ophthalmological section of the IVth Meeting of the Society of natural scientists and physicians in Poland (Posen, Juni 1884.- Ksiazko jubileuszowo, 1884)

Szokalski recommended intensively treating inflammatory conjunctival diseases with antiseptics, and that they should be applied by compresses on the eye but not via eye drops. He successfully treated using antiseptic-astringent lotions such as Aqua Prunipadi, boric acid, or zincum aceticum.

B. PUBLICATIONS IN GENERAL MEDICINE

Szokalski did not only publish in the field of ophthalmology. As a physician with experience in general medicine, he published numerous articles on general diseases. Many publications in the German language were written when he was living in France.

Some of these are mentioned in the following chronological order:

Szokalski VF. *Der Weichselzopf, betrachtet vom gegenwärtigen Zustande der Wissenschaft*.

Vorgetragen in der medico-practischen Gesellschaft und im Verein deutscher Ärzte zu Paris. *Arch Physiol Heilkd* 1845; 4: 333-377 (Dermatologic topic and topic of internal medicine:

The "Weichsel" pigtail ("Weichselzopf") considered from the present state of scientific knowledge, 1845)

Szokalski reported in this article his experience with patients whose hair was trichomatous and sticky. The cause of this condition was thought to be uncleanliness and poor personal hygiene causing headaches, migraine, dizziness, circulatory problems, and hypochondria.

Szokalski VF. *Die Geschichte und die pathologische Anatomie des typhösen Fiebers bei den Kindern*. *Journ Kinderkrankh* 1846; 7: 321-339; 401-411

("History and the pathological anatomy of typhoid fever in children", 1846)

¹⁰⁹ pp. 229, 230

¹¹⁰ pp. 231, 233.

Topic of pediatrics

Szokalski reported on the different stages and disease duration of typhoid fever in eight children. In the children who succumbed to the disease, they detected anomalous Peyer's plaques and mesenteric glands in the small intestines, anomalies were also detected in the spleen. Patients with typhoid fever often suffered from enteritis. Anomalies in the pharynx, throat, trachea, and esophagus (with membrane formation) were also described.

Szokalski VF. *Neun Briefe über den medicinischen Congress in Frankreich*. Arch Physiol Heilkd 1846; 5: 88-131 ("Nine letters on the medical congress in France", 1846)

Topic on medical organizations

In this publication, Szokalski discussed the organization of physicians and medical congresses in France. He mentioned that more than 2000 physicians lived in Paris. Besides the medical academy, there were 15 medical societies.¹¹¹ He described the education, training courses and lessons for students in the large French cities. Students had to work in a physician's practice for at least six years or in a hospital for five years and to study at the university for three years. Three professors had to examine one candidate.¹¹² Everybody had to swear the oath of Hippocrates before becoming a physician.

Szokalski VF. *Die Hospitäler und Wohltätigkeitsanstalten von Paris, nebst ihrer Statistik des Jahres 1845*. Arch Phys Heilkd 1847; 6: 208-317 ("Hospitals and welfare institutions in Paris and their statistics of 1845", 1847)

Topic on medical organization

Szokalski reported that in the year 1846 there were 86 physicians, 41 surgeons, 17 pharmacists, and 187 internists employed in hospitals in Paris. Medical doctors in a hospital had to be at least 35 years of age and

surgeons at least 30 years old. Szokalski mentioned seven hospitals and their numbers of beds. The biggest was the hospital "Hôtel-Dieu" with 810 beds; the smallest was the hospital "Cochin" with 130 beds. In the medical departments, the number of patients discharged healthy versus dead patients was 1: 8.4; in surgical departments 1 : 18.8. XXIII. Szokalski VF. *Über Wechselfieber mit langen Perioden*. Arch Physiol Heilkd 1848; 7: 403-414 ("On intermittent fever with long periods", 1848)

Topic of internal medicine

Szokalski examined and treated two children with intermittent fever over ten years of his practical experience in Paris. The cause of this disease in the two patients could not be identified. A disease caused by worms was considered.

Szokalski VF. *Von den Hühneraugen, Druckbeulen und den sonstigen pathologischen Druckprodukten der Füße*. Allgem Medic. Central-Zeitung 1848; 17: 666-671 ("On clavus, corns and other pathological anomalies caused by pressure on the feet").

Dermatological and surgical topic

Szokalski differentiated between callus, clavus, a pressure-induced corn and other anomalies in the feet caused by pressure. He mentioned that it was the fashion during the French revolution to wear boots with high heels which were pointed in shape. He found that boots of this kind had often caused foot problems.¹¹³ He observed that despite the manufacture of more comfortable shoes, pathologic skin problems in the feet still occurred. He recommended the prophylaxis and operative treatment of foot diseases.¹¹⁴

Szokalski VF. *Zur Medicinal-Reform in Frankreich II. Die constitutionell-monarchische Medicinal-Bewegung in Frankreich*. Neue Zeitung Medicin u. Medicinal-Reform 1849; 69: 554-555; 562-563 ("Concerning the medical reform in France II. The constitutional-monarchic medical movement in France", 1849)

¹¹¹ p. 92.

¹¹² p. 110.

¹¹³ p. 668.

¹¹⁴ pp. 670, 671.

Topic on medical organization

In this article Szokalski pointed to the medical new reform in France with the agreement of complete equality of rights and duties for physicians and the foundation of a medical board with the representation of Physicians's common interests. The medical board should influence the medical instruction with freedom for every physician to present medical lessons. In addition, the reform included the cooperation of the medical corporation in relation to the state with the occupation in medical official agencies.¹¹⁵

Szokalski VF. *Von den Fettbrüchen und bruchförmigen Fettmassen*. Arch Phys Heilkd 1850; 9: 611-624
("Fatty hernias and hernia-like fatty masses", 1850)

Surgical topic

With this publication, Szokalski emphasized that it is important to be knowledgeable of the difference between a fatty hernia as opposed to a genuine inguinal hernia. In case of a fatty hernia, the hernial sack is filled with fat, not viscera.

Szokalski VF. *Ein seltener Fall von Hydrarthrus im Schultergelenke*. Arch prakt Heilkd 1850; 9: 480-485
("A rare case with hydrarthrosis of the shoulder joint", 1850)
(Szokalski, physician at the Hospital d'Alice St.Reine, Burgundy)

Orthopedic topic

A 50-year-old with an enormous effusion in the left shoulder joint causing swelling and an edematous thickened left arm underwent several punctures in the joint cavity, however the release of fluid only reduced the swelling temporarily for several days. Punctures were carried out again without success. Szokalski argued that attrition of the joint's cartilage with secondary secretion of the joint capsule was the cause of the hydrarthrosis. The patient died several weeks later.

¹¹⁵ p. 555.

Szokalski VF. *Von der Anästhesie und der Hyperästhesie bei den hysterischen Frauen*. Vierteljahresschrift prakt Med 1851; 9: 130-150
("On anesthesia and the hyperesthesia of hysterical women", 1851)

Psychiatric topic

Szokalski reported on his experience with 17 women who had anesthetic parts of their body.¹¹⁶ Some of the hysterical women revealed signs of hyperesthesia.¹¹⁷ He also mentioned hysterical torticollis resulting from cervical muscular cramps occurring in some patients.¹¹⁸ Szokalski concluded that anesthesia, hyperesthesia or cramps following hysterical attacks occur in conjunction with irritation to the peripheral nervous system. These changes were observed more often in the sensoric system than the locomotoric system.¹¹⁹ He postulated that changes in the medulla oblongata are the cause of the physical symptoms and features.¹²⁰

C. Literature about W.F. Szokalski

Orlowski W. J. *Verbindungen polnischer Augenärzte des XIX. Jahrhunderts mit der deutschen Augenheilkunde*. Fortschr Ophthalmol 1987; 84: 669-672

(Contacts between Polish and German ophthalmologists in the 19th century, 1987)

Professor W. J. Orlowski, Director of the University Eye Clinic of the Medical Academy Karol Marcinkowski in Poznan/Poland published the following Abstract in his German presentation at the 83rd meeting of the German Ophthalmological Society in Heidelberg in 1987:

"The author discusses the reasons why Poles had to study at foreign universities at that time, including those in Germany. Only the Polish territories belonging to Austria had universities (Krakau and Lemberg), in the territories belonging to Russia, the Russians had taken control of Vilno University already in 1772, the medical faculty in Warsaw had been

¹¹⁶ p. 130.

¹¹⁷ p. 135.

¹¹⁸ p.144.

¹¹⁹ pp. 145, 146.

¹²⁰ p. 150.

completely “russified” several times from 1817 and since 1869, and thus many Poles preferred to study in Russia rather than in Poland in the Russian language. In the territories belonging to Prussia there were no academic institutions. Another reason was banishment of many young Poles after many insurrections against the occupants, especially in 1831 and 1863. These factors explain why Poles both studied and specialized in various research fields in other countries including Germany, and frequently published papers, articles, and books in other languages, as did Szokalski“.

Orlowski (1987) reported the curriculum vitae of Wiktor Feliks Szokalski, the father of Polish ophthalmology. Szokalski studied at the Royal University in Warsaw for two or three years. This university was called Alexander University because Czar Alexander had founded it in 1816. Szokalski participated in the November revolt (1830-1831). It was his duty to assist the battalion physician; he also substituted for the physician. Szokalski became famous after having ligated the thigh artery of a badly wounded artillery officer. After passing the Prussian frontier near Tczew with his regiment and the entire army corps, Szokalski worked in a Polish military hospital for nearly half a year. There he was awarded the golden cross “*Virtuti Militari*, IV. class”, the highest Polish military award, founded by King Stanislaw in August 1792. From there, Szokalski went into exile to France. On the way interrupted his journey in Gießen, Germany, where he remained from May 1832 to 1834 to continue his medical studies. He then completed his degree in Heidelberg and Würzburg. His thesis “*De facie hippocratica*” (1834) was his only publication in Germany. He published a total of 179 works, 30 of which were written in the German language. When Szokalski came to Paris, his degree and thesis from Germany were not recognized in France. His second thesis, this time in French, was written in 1839. When thanks to an amnesty he returned to Warsaw on October 23rd, 1853, he had to write his third thesis, despite the fact that Jagellonic University at Krakau had appointed him as a university lecturer in ophthalmology. However, that appointment had not been confirmed by the government in Vienna. In addition to Szokalski’s brief curriculum vitae, Orlowski mentioned other important

Polish ophthalmologists of the 19th century in his presentation, especially Boleslaw Wiktor Wicherkiewicz (1847-1915), the other great Polish ophthalmologist of that century.

Talko, Josef: *Prof. Dr. Szokalski and his activity and a collection of the literature on history of Ophthalmology in Poland from the beginning to our days*, Warsaw, printed by M. Ziemkiavicz and W. Noakorski, 1884, *Klin Monatsbl Augenheilkd* 1884; 22: 425-428.

Talko reported that at the 4th meeting of the Polish Society of Physicians and Natural Scientists in June 1884, Professor Szokalski was named Honorary President of the Society. Talko presented him with a splendid edition of his new book, a collection of the literature on the history of ophthalmology in Poland from the beginning to the present. This 143-page book consists of two parts.

In the first part Szokalski’s biography with his memory is documented. In the second part, Szokalski published the history of Polish ophthalmology.¹²¹ Talko stated that there was nearly no topic on which Szokalski had not published in physiology, medicine, and hygienics. His 2-volume textbook in ophthalmology in humans had been translated into Russian by Woinow. Talko also mentioned the 25-year anniversary of Szokalski’s directorship at the Lubomirski’s Institute of Ophthalmology.¹²²

The second part of Szokalski’s book contains a compilation of all Polish physicians who made important contributions to the Polish ophthalmological literature and all Polish ophthalmologists who had practiced in Poland or abroad. He also mentioned all the professors who had contributed to ophthalmology at the Polish Universities (in Cracow, Warsaw, Vilnius, Lviv) and all private ophthalmologists and all ophthalmological institutes: University Eye Clinic in Warsaw, Prince Lubomirski’s Institute of Ophthalmology in Warsaw, Eye clinics on Poznan, Vilnius, ophthalmological departments in the hospitals (“Child Jesus”) in Warsaw, the Jewish hospital in Warsaw, hospital in Lviv, Dr. Dotzanski’s private eye clinic in Warsaw, ophthalmological department in the chil-

¹²¹ p. 425.

¹²² p. 426.

dren's hospital in Warsaw, etc. This second part of the book can be regarded as a kind of storehouse for bibliographic studies.¹²³

Talko J. *Jubilee of Prof. Dr. Szokalski*. Klin Monatsbl Augenheilkd 1879; 17: 201-204

Talko reported that the 25th anniversary of director Prof. Dr. W. Szokalski's was celebrated in the halls of Prince Lubomirski's Institute of Ophthalmology on April 8th, 1879. In attendance were Prince Lubomirski and many of Szokalski's colleagues and friends., Szokalski was given portraits of 15 Polish ophthalmologists with a picture of Szokalski and the words: "For the 'nestor' of Polish ophthalmologists on the day of his 25-year anniversary, in honor of his equal importance to science and his patients".

Dr. Talko gave the main speech. He mentioned that Prince Eduard Lubomirski had founded an ophthalmological institute in Warsaw half a century previously. At that time, almost no one in western Europe had considered establishing such institutes, and there were no such institutions in the regions east of the Weichsel. The oldest hospital for eye patients had been opened in Prague in 1790. Eye hospitals had been founded later: in 1811 in Vienna, 1814 in Manchester, and 1820 in Leipzig. The hospitals in Birmingham and Munich were opened at the same time as the Lubomirski Institute, in 1823. A similar hospital in Moscow was established in 1826. The Lubomirski Institute was established long before the others in eastern and western Europe. The Institute's 50 years of experience had proven fruitful for medical science and for Poland, and everybody was convinced that it would be beneficial in the future as long as its administration remained in the hands of scientists. In the beginning, in 1835, the Institute cooperated with the general hospital. The Lubomirski Institute's move to a new building, and access to its excellent equipment, were primarily thanks to Dr. Szokalski and Prince Lubomirski's family. During the first half of the Institute's existence it was directed by a Dr. Hilferding. Dr. Szokalski directed it in the second half. Talko expressed his gratitude and warm appreciation, also on the behalf of Poland, for Szokalski's direction of the Institute and ex-

pressed his warmest wishes for Szokalski's future. After Talko's speech, Professor Walther, inspector of Warsaw's hospitals, congratulated Szokalski and promised that the city's administration, in acknowledgement of Szokalski's scientific achievements, would raise his salary. During the evening's festivities, Prince Lubomirski honored Szokalski and other colleagues and former pupils of the assembly with 60 guests, praising the merit of the celebrated Szokalski.

Talko, *publication of the 50-year anniversary celebration of Prof. Dr. Victor Szokalski in Warsaw, dedicated by Polish ophthalmologists* (editor Dr. J. Talko, publisher Dr. M. v. Kepinski, Warsaw 1884 (410 pages with a portrait of Professor Szokalski); Centralbl. prakt. Augenheilkd. 1884; 8: 404-406

Here Dr. Talko wrote Szokalski's biography and discussed the history of ophthalmology in Poland. It contains several articles on ophthalmological topics, for instance by Dr. Conrad Rumszswicz (Kiev), Professor Schöbl (Prague), Dr. Zygmunt Kramsztyk (Warsaw), Dr. Karol Szadek (Kiev), Professor X. Galezowski (Paris), Dr. Felix Winawer (Warsaw), Dr. Zenon Winawer (Warsaw), Dr. Henryk Zapolski-Downar (Lublin) und others.

Fritz, Josef (Dr. med et phil from Lemberg): Presentation at the German Society's Meeting of Medical History and Natural Sciences in Homburg vor der Höhe, on September 21st, 1927: "*Erinnerungen an Deutsche Medizin in den Memoiren des Polnischen Augenarztes W. Szokalski*"; In: JANUS, Archives Internationales pour l'histoire de la Médecine et la Géographie Médicale 1928; 32: 243-254, Librairie et Imprimerie E. J. Brill, Leyde, 1928

Fritz reported that Szokalski was a good acquaintance of Richard Wagner, who introduced him to the art of music. When Szokalski was young, he was an admirer of German poets, particularly Goethe and Schiller. After the Polish revolt against Russia was defeated in 1830, he decided to stay in Germany to continue his medical studies. At that time there were many in Germany who sympathized with the Polish freedom fighters. Several German associations collected money to support the Polish revolt and

¹²³ p. 427.

later, for refugees' scholarships to study in southern Germany. With this financial support, the freedom fighters could study at German universities. The refugees were warmly received by democratic German societies such as the associations of students, the German "Burschenschaft" in the university cities of Leipzig, Jena, and Frankfurt.¹²⁴ The German family Budden helped him to continue his medical study at Gießen University. As authorities of the university-professors, notified in Szokalski's memoirs, Szokalski admired Friedrich Wilhelm Vogt, the pathologist, and Justus Liebig, the chemist. All the professors at Gießen University were good lecturers. Szokalski befriended Karl Vogt and Friedrich Werneking, the anatomist.¹²⁵ Szokalski also got to know Dr. Glaser from Grünberg who ran a well-known homeopathy practice; Szokalski studied ophthalmology under Georg Balsler in Gießen. Szokalski assisted Dr. Glaser in his practice in Grünberg, but Szokalski was sceptical of the merits of homeopathic medicine. At that time, Szokalski decided to move to Heidelberg, where he studied pediatrics under Friedrich August Puchelt. There, he learned how to conduct percussion and auscultation.¹²⁶ In Heidelberg, Szokalski learned how to precisely conduct a scientifically-based medical examination on patients. He was impressed by the lectures of Franz Karl Naegele the obstetrician, by Friedrich Tiedemann the anatomist, and by Ludwig Bischoff the physiologist. Szokalski found the surgeon and ophthalmologist M.J. Chelius less impressive.¹²⁷ After studying in Heidelberg, he returned to Gießen. He received permission to practice in Vogelsburg, but then decided to go to Paris; he was financially aided by a gift of 300 florins ("Gulden") by thankful citizens of Grünberg. Szokalski's became engaged to marry Luise Langsdorf, the niece of Justus Liebig, in 1837. He later married her. In Paris, Szokalski was assistant at Sichel's clinic, then the largest practice in Paris. Sichel had studied ophthalmology in Vienna under Friedrich Jaeger. Sichel gave Szokalski 300 eye specimens to examine and describe; they had formed the basis of Sichel's atlas on eye diseases. Szokalski learned about the

pathological anatomy of the eyes by studying these specimens and came into contact with the famous French scientists Cruveilhier and Malgaigne. In Paris, Szokalski got to know the musician Kühn. The Kühn family were the center of the German population's social life in Paris. Richard Wagner and his sister were guests at the Kühn home. Szokalski translated Ammon's atlas into French, an endeavor arranged by Kühn.¹²⁸ There were 60000 Germans living in Paris at that time. Szokalski therefore got the idea in 1841 to found the Society of German Physicians in Paris, a society that soon had many members. The society first met in Szokalski's home, later in a larger room in a university building belonging to the medical faculty, after being given permission by the university dean. The meetings took place once a week. Szokalski was president of the society for four years. Famous physicians from Austria and Germany attended sessions of the society, eg, Rokitansky, Skoda, Kölliker, Virchow, Karl Vogt, Stromeyer, Graefe, Volkmann, and others. French physicians also participated in the meetings. They thus constituted a highly respected and instructional organization for German medical doctors in Paris working in hospitals or practices. Szokalski was grateful for the knowledge he had gained during his studies at German universities before moving to France. The University in Gießen dedicated him in honour his doctoral thesis¹²⁹

Talko, Joseph. *Nekrolog Victor Felix Szokalski*, *Klin. Monatsbl. Augenheilkd* 1891; 29: 78-81

Talko describes the essential events in Szokalski's life. In this article, he states that in 1882, Szokalski was named lifelong secretary of the Warsaw Medical Association. Two years later, he celebrated his 50-year career as a physician. Beyond the private festivities, he received congratulations from French, German, Russian, and Italian colleagues. The Russian government awarded him the Order of the Holy Wladimir; Dr. Talko and Dr. Kempinski gave him a "Szokalski album". Every Polish ophthalmologist had helped fill this album containing Szokalski's biography and all his publications. Szokalski was given the first Great

¹²⁴ p. 244.

¹²⁵ pp. 245, 246.

¹²⁶ pp. 247, 248.

¹²⁷ p. 249.

¹²⁸ pp. 250-252.

¹²⁹ pp. 253, 254.

Prince Ljubomirski Award by the Cracow Scientific Society for his important textbook "Ophthalmology in Humans". This textbook was regarded as the finest work in the field of ophthalmology in the Polish language. Professor Szokalski was considered a deep critical thinker who did not rely merely on what he had learned earlier – he was a physician who continued pursuing knowledge by conducting research, and who kept informed on the progress in science all his life. His tomb was decorated with a monument, and a bust was erected in the hall of the Warsaw Medical Society.

A Selection of Publications by Szokalski in German Language in Chronologic order.

Szokalski VF. *Über die Empfindungen der Farben in physiologischer und pathologischer Hinsicht* (1842). Eine der Academie der Wissenschaften zu Paris vorgelegte Abhandlung von Victor Szokalski, Doctor der Medicin, der Chirurgie und Geburtshilfe der Facultäten zu Gießen und Paris, Professor der Augenheilkunde zu Paris, Mitglied mehrerer gelehrten Gesellschaften. J. Ricker'sche Buchhandlung, Gießen 1842.

Szokalski VF. *Angeborene Geschwulst an der Sklerotica des rechten Auges*. Journal Chirurg u. Augenheilkd 1843: 90-95

Szokalski VF. *Von der Abtragung des Pterygiums vermittelt der Ligatur*. Arch Physiol Heilkd 1845; 4: 285-295

Szokalski VF. *Drei Beobachtungen aus der augenärztlichen Praxis, vorgetragen in dem Vereine der deutschen Ärzte zu Paris von dem Begründer derselben Dr. Victor Szokalski, Ärzte des 7. Arrondissements der Stadt Paris*. Vierteljahresschrift prakt Heilkd 1846; 4: 18-29

Szokalski VF. *Von den Trübungen der Hornhaut in histologischer Hinsicht mit Bezug auf Augenpraxis*. Arch Physiol Heilkd 1846; 5: 183-237

Szokalski VF. *Das Abschaben der Hornhautflecken*. Arch Physiol Heilkd 1847; &: 638-641

Szokalski VF. *Das Doppeltsehen mit einem Auge*. Vierteljahresschrift prakt Heilkd 1847; 2: 22-44

Szokalski VF. *Über die hygienische und therapeutische Anwendung der Schutzbrillen und der optischen Gläser*. Vierteljahresschrift prakt Heilkd 1848; 6: 139-172

Szokalski VF. *Das Anpassungsvermögen des Auges vom pathologischen Gesichtspunkte aus betrachtet*. Arch Physiol Heilkd 1848; 7: 695-709

Szokalski VF. *Briefe über die Behandlung chronischer Augenentzündungen*. Allgem Med Central-Zeitung 1848; 17: 170-171; 178-183; 186-191; 194-198

Szokalski VF. *Ueber den Einfluss des fünften Nervenpaares auf das Sehvermögen*. Arch Physiol Heilkd 1849; 8: 317-349

Szokalski VF. *Von den unmittelbaren Sehorganen mit Rücksicht auf die Cerebralstörungen der Gesichtsfuction*. In: Vierteljahrschrift Prakt Heilkunde (Hrsg. Med. Fakultät Prag, Redaktion J. Halla, J. v. Hasner) 1854; 1. Bd. Verlag Karl André Prag; S. 65-108

Szokalski VF. *Papilloma corneae*. Klin Monatsbl Augenheilkd 1864; 2: 326-328

Szokalski VF. *Aneurysma traumaticum diffusum in der Augenhöhle*. Klin Monatsbl Augenheilkd 1864; 2: 427-431; Vierteljahresschrift prakt Heilkd 1865; 22: 91-92

Szokalski VF. *Glioma malignum retinae*. Klin Monatsbl Augenheilkd 1865; 3: 396-404

Szokalski VF. *Von der electrisch-gymnastischen Behandlung der Augenmuskelparesen*. Klin Monatsbl Augenheilkd 1865; 3: 226-236

Talko J. *Entropium spasticum operiert mittelst einer neuen von Dr. Prof. Szokalski angegebenen Methode*. Klin Monatsbl Augenheilkd 1872; 10: 25-29

Szokalski VF. *Ueber die Krankheiten der Conjunctiva und deren Behandlung*. In: Bericht über die augenärztliche Section der IV. polnischen Naturforscher- und Ärzte-Versammlung (Posen, Juni 1884.- Ksiazko jubileuszowo 1884, p. 362; Centralbl Augenheilkd 1884; 8: 403.

General Medicine

Szokalski VF. *Der Weichselzopf, betrachtet vom gegenwärtigen Zustande der Wissenschaft*. Vorgetragen in der medico-practischen Gesellschaft und im Verein deutscher Ärzte zu Paris. Arch Physiol Heilkd 1845; 4: 333-377

Szokalski VF. *Die Geschichte und die pathologische Anatomie des typhösen Fiebers bei den Kindern*. Journ Kinderkrankh 1846; 7: 321-339; 401-411

Szokalski VF. *Neun Briefe über den medicinischen Congress in Frankreich*. Arch Physiol Heilkd 1846; 5: 88-131

Szokalski VF. *Die Hospitäler und Wohltätigkeitsanstalten von Paris, nebst ihrer Statistik des Jahres 1845*. Arch Phys Heilkd 1847; 6: 208-317

Szokalski VF. *Über Wechselieber mit langen Perioden*. Arch Physiol Heilkd 1848; 7: 403-414

Szokalski VF. *Von den Hühneraugen, Druckbeulen und den sonstigen pathologischen Druckprodukten der Füße*. Allgem Medic Cental-Zeitung 1848; 17: 666-671

Szokalski VF. *Zur Medicinal-Reform in Frankreich II. Die constitutionell-monarchische Medicinal-Bewegung in Frankreich*. Neue Zeitung Medicin u. Medicinal-Reform 1849; 69: 554-555; 562-563

Szokalski VF. *Von den Fettbrüchen und bruchförmigen Fettmassen*. Arch Phys Heilkd 1850; 9: 611-624

Szokalski VF. *Ein seltener Fall von Hydrarthrus im Schultergelenke*. Arch prakt Heilkd 1850; 9: 480-485

Szokalski VF. *Von der Anästhesie und der Hyperästhesie bei den hysterischen Frauen*. Vierteljahresschrift prakt Med 1851; 9: 130-150

About Wiktor Szokalski in ophthalmic literature

Fritz, Josef (Dr. med et phil from Lwów): Presentation at the German Society's Meeting of Medical History and Natural Sciences in Homburg vor der Höhe, on September 21st,

1927: "Erinnerungen an Deutsche Medizin in den Memoiren des Polnischen Augenarztes W. Szokalski"; In: JANUS, Archives Internationales pour l'histoire de la Médecine et la Géographie Médicale 1928; 32: 243-254, Librairie et Imprimerie E. J. Brill, Leyde, 1928

Orlowski W.J. *Verbindungen polnischer Augenärzte des XIX. Jahrhunderts mit der deutschen Augenheilkunde*. Fortschr Ophthalmol 1987; 84: 669-672

Talko, Josef: *Prof. Dr. Szokalski und his activity and a collection of the literature on history of Ophthalmology in Poland from the beginning to our days*, Warsaw, printed by M. Ziemkiawicz and W. Noakorski, 1884, Klin. Monatsbl. Augenheilkd. 1884; 22: 425-428.

Talko J. *Jubilee of Prof. Dr. Szokalski*. Klin. Monatsbl. Augenheilkd. 1879; 17: 201-204

Talko, publication of the 50-year doctor's jubilee of Prof. Dr. Victor Szokalski in Warsaw, dedicated by Polish ophthalmologists (editor Dr. J. Talko, publisher Dr. M. v. Kepinski, Warsaw 1884 (410 pages with a portrait of Professor Szokalski).

Centralbl. prakt. Augenheilkd. 1884; 8: 404-406

Talko, Joseph. *Nekrolog Victor Felix Szokalski*, Klin. Monatsbl. Augenheilkd 1891; 29: 78-81